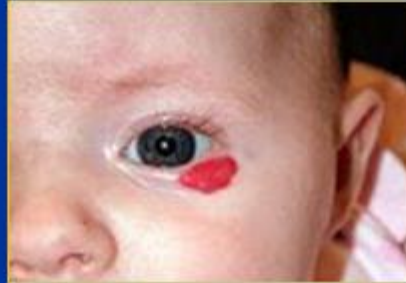

# 11- DD: Red in eye (symptom & sign)

Location of red lesions	Differential diagnosis
Red on lid	Capillary hemangioma
Red in conjunctiva	See Red eye: section 3.0
Red in cornea	Pterygium / blood vessels
Red in anterior chamber	HypHEMA
Red on iris	Iris new vessels
Red in vitreous	Vitreous hemorrhage
Red on retina: Small flame shaped	Retinal venous occlusions
Red on retina: Flame shaped with hard exudates	Diabetic retinopathy, Hypertensive retinopathy
Red on retina: Large hemorrhage	Diabetic retinopathy, ARMD, Retinal tear
Red in macula	Macular hole, CRAO, Macular hemorrhage
Red on disc	Disc edema, Disc new vessels

## Red on eye lid

### Red on lid



**Capillary hemangioma**  
Bright red lesion on eye lid or around

## Red on conjunctiva

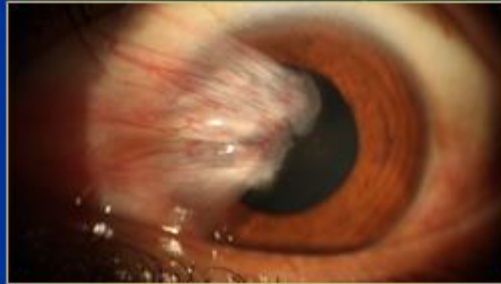
### Red conjunctiva (see 3.0- DD red /gritty eye)

8:5:5:2

	8 Conjunctival/sclera	5 Cornea	5 Lid	2 AC
Localized	Obscuring vessels	Abrasion	Stye	Uveitis
	Localized bulbar	FB	Chalazion	ACG
	Leash of vessels	Peripheral keratitis	Blepharitis	
Generalized	Circumcorneal	Central keratitis	Preseptal cellulitis	
	Fornix (Exudation/discharge)	Tuft of vessels	Dacrocystitis	
	Mainly palpebral			
	Generalized swelling			
	General redness			

## Red on Cornea

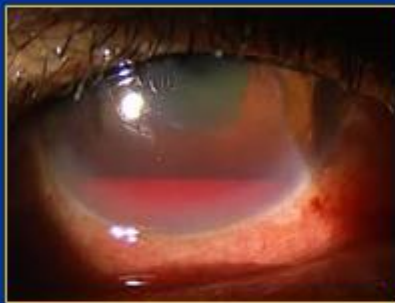### Red on cornea



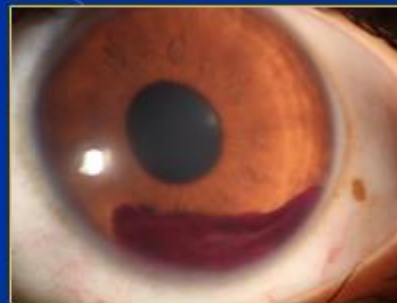
**Pterygium (also as red conjunctiva)**  
Whitish lesion with red blood vessels

## Red in anterior chamber

### Red in anterior chamber



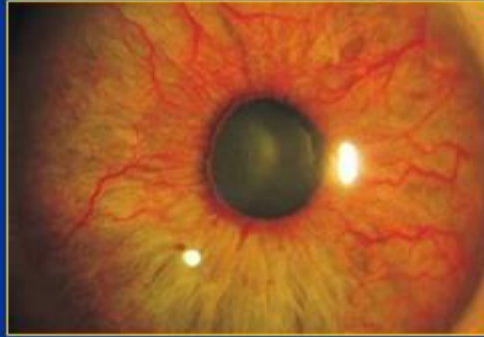**Hyphema**  
Cause: Trauma and new vessels



**Clot in anterior chamber**  
Hyphema get converted in to clot

## Red on iris

### Red on iris

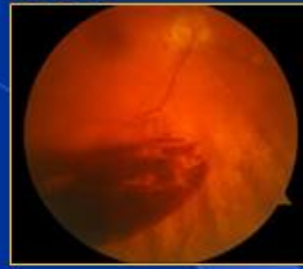


#### Iris new vessels

Causes: Same cause as for big retinal hemorrhage

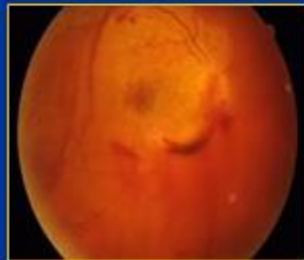
## Red in Vitreous

### Red in vitreous



#### Vitreous hemorrhage: Large & irregular (Always out of focus)

Causes : Diabetic retinopathy, CRVO, Retinal detachment, ARMD, Vascular ischemia in uveitis

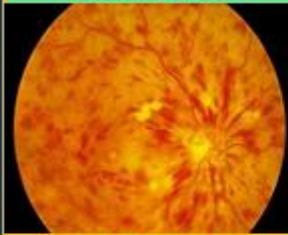


#### Total vitreous hemorrhage (NO VIEW)

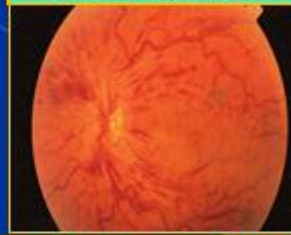## Red on Retina: Flame shaped hemorrhages

### Red on retina: Flame shaped (No hard exudates)

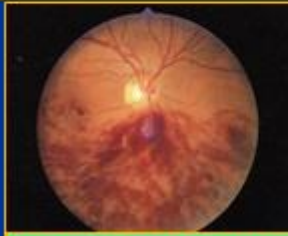Ischemic CRVO



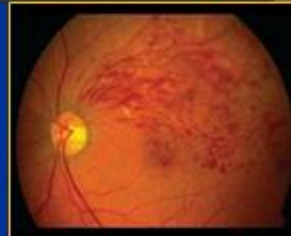Non ischemic CRVO



**Vascular occlusion: Total (ischemic & non-ichemic) & partial (Hemi & BRVO)**  
Central retinal vein occlusion (CRVO) is acute condition so no time to develop hard exudates



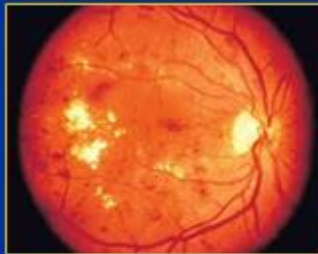Hemi retinal vein occlusion



Branch retinal vein occlusion

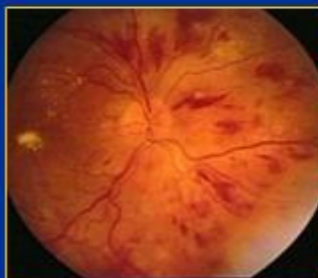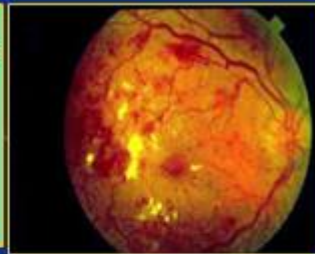
## Red on Retina: Flame shaped hemorrhages & hard exudates

### Red on retina: Flame shaped & hard exudates



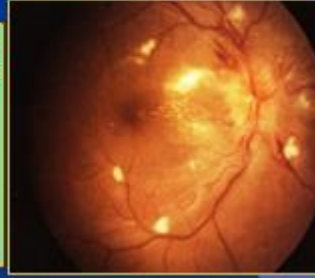**Diabetic retinopathy**  
Red flame shaped hemorrhages  
and hard exudates  
ALONG WITH

- Microaneurysms
- Cotton wool spots
- New vessels



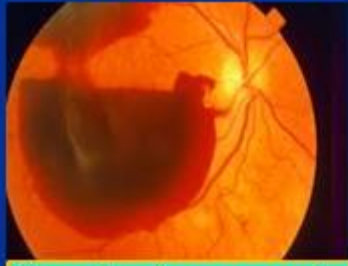
**Hypertensive retinopathy**  
Red flame shaped hemorrhages  
and hard exudates  
ALONG WITH

- Cotton wool spots
- Arteriole narrowing
- Disc edema

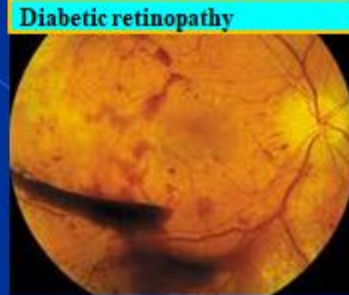

## Red on Retina: Big irregular hemorrhage

### Red on retina: Big irregular hemorrhage

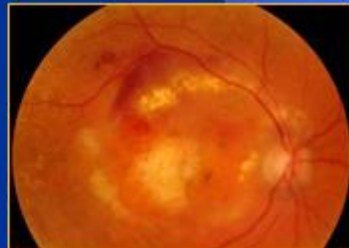

Hemorrhage from new vessels



Diabetic retinopathy

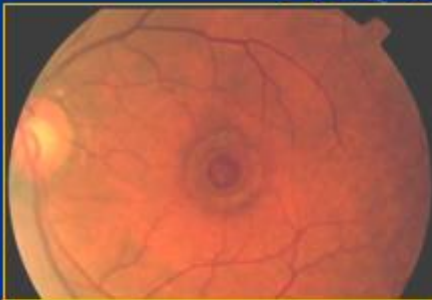
- Causes of big retinal hemorrhages are (same as in vitreous hemorrhage)
- New vessels bleed in diabetic retinopathy
  - New vessels bleed in vascular occlusions
  - Bleeding from exudative ARMD
  - Bleeding from retinal tear



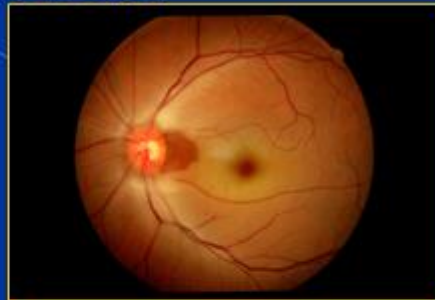Exudative ARMD hemorrhage

## Red on Macula

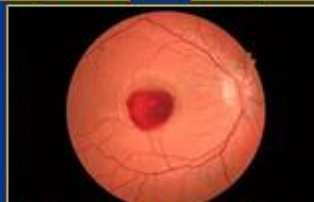### Red in macula



Macular hole  
Edge of macular hole with surrounding edema

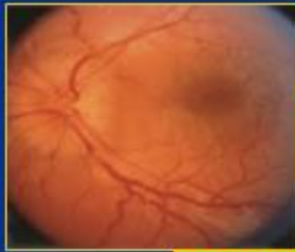

Cherry red spot in CRAO  
No edge as it is macular reflex in macular edema

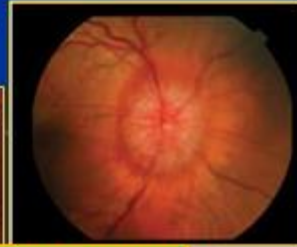

Central macular hemorrhage  
ARMD, branch vein occlusion, trauma

## Red on disc



**Pinkish normal disc**  
Clear margin  
Whitish cup 0.3 CD



**Disc edema: Blurred margins, hyperemic with loss of cup**  
Causes: Papilledema, Hypertensive retinopathy, Optic neuritis

**Disc new vessels**  
Causes: Diabetic retinopathy, Vascular occlusion, Uveitis

